

Effects of Mandibular Posture on Obstructive Sleep Apnea Severity and the Temporomandibular Joint in Patients Fitted with an Oral Appliance

Fernanda Ribeiro de Almeida MSc,¹ Lia Rita Bittencourt PhD,² Clemente Isnard Ribeiro de Almeida PhD,³ Satoru Tsuiki PhD,¹ Alan A. Lowe PhD,¹ and Sérgio Tufik PhD²

¹Department of Oral Health Sciences, The University of British Columbia, Vancouver, Canada; ²Psychobiology Department, Division of Sleep Medicine and Biology, Federal University of São Paulo, São Paulo, Brazil; ³Department of Otolaryngology, Faculty of Medical Sciences of Santa Casa São Paulo, São Paulo, Brazil

Study Objectives: The purposes of this study were to assess the relationship between different increments of mandibular protrusion and a reduction of obstructive sleep apnea (OSA) severity and to use magnetic resonance imaging to assess temporomandibular joint (TMJ) morphology and condyle position after the insertion of an oral appliance (OA).

Design: Six mild to moderate OSA patients were treated with a titratable OA (Klearway™) and changes in the apnea hypopnea index (AHI) secondary to the amount of mandibular advancement were evaluated. In seven patients, the morphology of the TMJ was compared before insertion and after titration of the appliance and the anterior displacement of the condyle with the titrated appliance in place was evaluated.

Setting: Federal University of São Paulo, Brazil.

Patients or Participants: 7 males (mean age 47.4 years, SD 5.6).

Interventions: N/A

Measurements and Results: A total of 21 polysomnographic recordings in different mandibular positions were compared. A significant reduction in the mean AHI from 12.21 to 5.64 was seen and the the AHI reduction was related to the amount of mandibular protrusion. In six out of seven patients, the translation of the condyle with the OA was equal to or less than that observed in the maximal open position. No TMJ morphologic parameters revealed significant alterations during the period of the study.

Conclusion: Sequential polysomnographic studies facilitate OA titration. OA effects on the AHI seem to be dose-dependent on the amount of mandibular protrusion, and the OA proved over the period of one year to be innocuous for TMJ in the treatment of patients with OSA.

Key words: Obstructive sleep apnea (OSA); mandibular advancement; titratable oral appliance; magnetic resonance imaging (MRI); side effects.

INTRODUCTION

ORAL APPLIANCES (OAs) APPEAR TO BE NONINVASIVE, SIMPLE, WELL-TOLERATED AND EFFICIENT AND THEIR USE HAS DRAMATICALLY INCREASED IN OBSTRUCTIVE SLEEP APNEA (OSA) PATIENTS. Various studies have assessed OA efficiency and report up to 80% success rates in mild OSA patients¹ and 60% in more severe cases.^{1,2} A number of imaging studies using cephalometry,³ videodensitometry,⁴ computed tomography⁵ and/or magnetic resonance imaging (MRI)⁶ have shown that OAs advance the mandible forward and change the volume of the upper airway.

Recently the ability to titrate OAs over time has significantly improved their efficacy.⁷ This fact may be related to a dose-dependent enlargement of the upper airway (UA),³ augmentation of UA muscle activity⁸ and improvement of minimum SaO₂⁹ due to mandibular protrusion. Respiratory as well as sleep variables also demonstrate dose-dependent improvement. However, the acceptable range of mandibular advancement for each patient is not well understood, although it has been reported that the maxi-

mal protrusion of the mandible produces the greatest airway enlargement.^{3,10} A maximum forward mandibular position is not adequate since it can cause temporomandibular joint (TMJ), or muscle discomfort. Clinically, OSA symptoms decrease as the mandible is advanced, and each patient has a comfortable forward mandibular position in which reduction or cessation of OSA symptoms is reported.

Several OA trials for the treatment of OSA have evaluated the possible development of temporomandibular disorders (TMD) related to the use of OAs.¹¹⁻¹³ Some authors¹³⁻²² did not observe TMD in their studies, while others mentioned the appearance of TMD characterized by pain in the TMJ region or chewing muscles in a small number of cases in which OA treatment was discontinued.^{12,23-27} There is concern about possible osteoarticular problems, pain, occlusal changes, articular cavity changes, and condyle changes as a result of the mandibular advancement secondary to the use of an OA.

The purpose of this study was to define in sequential polysomnographic studies how the number of apneas is reduced by gradual forward titration of the mandible and to evaluate anatomical acceptability of the titrated mandibular position using MRI.

MATERIALS AND METHODS

Subjects

Seven patients with symptomatic mild to moderate OSA participated in this study. A physician screened patients from June 1998 to December 1999 in the Department of Medicine,

Disclosure Statement

Nothing to disclose.

Submitted for publication November 2001

Accepted for publication March 2002

Address correspondence to: Fernanda R. Almeida, DDS, MSc, Department of Oral Health Sciences, The University of British Columbia, 2199 Wesbrook Mall, Vancouver, B.C., Canada V6T 1Z3; Tel: (604) 822-3623; Fax: (604) 822-3562; E-mail: falmeida@interchange.ubc.ca

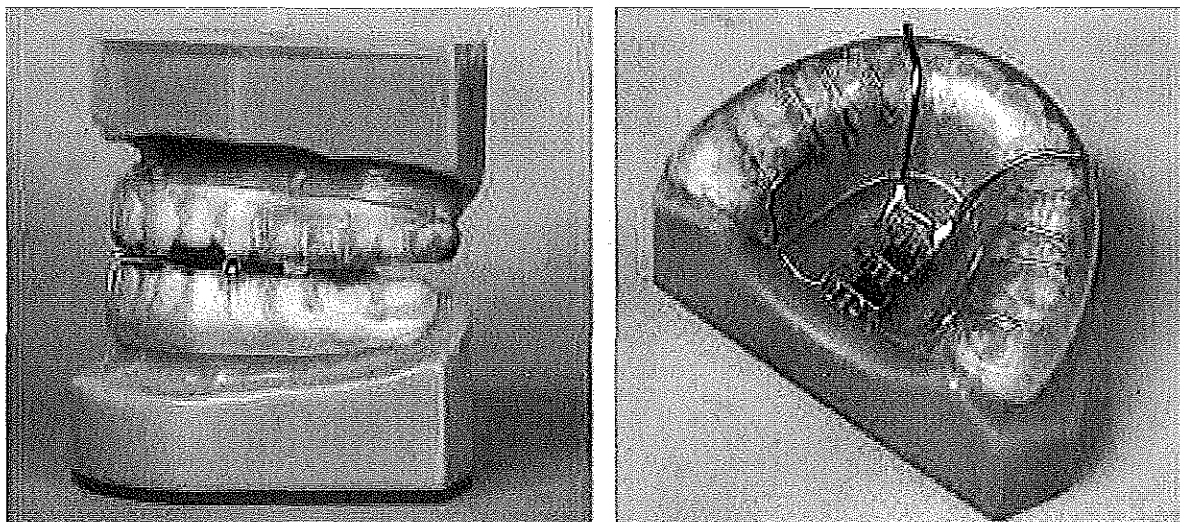


Figure 1—Lateral and maxillary arch views of the titratable oral appliance (Klearway™). The arrows show the position of the screw, which enables a total of 44 anterior positions of the mandible.

Discipline of Pneumology, Universidade Federal de São Paulo (UNIFESP). Polysomnographic recordings were performed at the Institute of Sleep and Electrodiagnosis of the Department of Psychobiology, UNIFESP. The equipment included Alice 3 machines with three channels for registering electroencephalogram (EEG), two for electrooculogram (EOG), two for electromyogram (EMG - submental and tibial), one for electrocardiogram (ECG), one for pulse oximetry, two for thorax and abdomen piezoelectric belts, and one for airflow with nasal-oral thermistor readings. Sleep staging and apnea and hypopnea characteristics were scored manually following the parameters of Rechtschaffen & Kales²⁸ and the American Academy of Sleep Medicine.²⁹ A dentist performed the dental evaluation of the inclusion and exclusion criteria for OA use. Patients with an apnea and hypopnea index (AHI) between 5 and 30 were accepted into this study if they were 25 years of age or older, had more than 10 teeth in each jaw,³⁰ had no symptoms related to temporomandibular disorder (TMD) and had a body mass index (BMI) less than 33 kg/m². Patients with clinical symptoms of a TMD were excluded according to the parameters of the American Sleep Disorders Association.³¹ All subjects were informed and signed a consent form which was approved by the Ethics Committee of UNIFESP, and were identified by numbers only.

Titratable Oral Appliance

For each patient, the occlusal registration at 60% of the maximum mandibular protrusion with 2 mm of vertical separation between the upper and lower incisors was recorded with a George Gauge®.³² A set of mandibular and maxillary models, together with an occlusal registration, were sent to Great Lakes Orthodontics Laboratory in Tonawanda, New York, USA, where the Klearway™ oral appliance³⁰ (Figure 1) was manufactured. The appliance was inserted, and titration of the mandible was performed until an OA therapeutic position, as defined by both clinical symptoms and polysomnographic studies, was reached. The therapeutic position was calculated as the initial 60%

advancement added to the amount of advancement done by the dentist. Clinical symptoms of reduced snoring, an improvement of symptoms, and the attainment of the maximum comfortable jaw position were used.

Magnetic Resonance Imaging

To investigate the anatomy and position of the condyle and disc of the TMJ, MRI of seven patients was obtained before insertion of the appliance and after OA titration at the Brasil Diagnostic Center, São Paulo, Brazil. Images were acquired with a 1.5 Tesla scanner machine (Sigma Advantage, General Electric, Milwaukee, WI) equipped with a TMJ surface coil. In order to trace pathologies and remodeling areas, T2-pondered images were obtained using fast spin-echo XL (TR 3200 ms, TE 87.7 ms, FOV 12 x 12 cm, 256 x 224 matrix, thickness 3.0/0.0 mm, TA 3' 12"). T1-pondered sequence images on fast spin-echo XL (TR 400 ms, TE 14.2 ms, FOV 12 x 12, 256 x 192 matrix, 3 NEX, thickness 3.0/0.0 mm and TA 3' 18") were perpendicular to the lateral length of the condyle. Increases in signal intensity (bright areas) were analyzed as active remodeling. Different bone shapes were interpreted as anatomic changes. These parameters were analyzed by visual inspection of the MRIs by the same radiologist. Morphology and signal intensity of the TMJ were evaluated and compared before and after OA insertion, and the following parameters were observed: anatomy and signal intensity of the chewing muscles, condyle, eminence, fossa, and position of the articular disc.³³ After the titration period of the appliance the MRI position of the condyle was evaluated in the maximum open position and in the titrated mandibular position. In order to mimic the titrated mandibular position, Optosil® silicone prototypes were used to reproduce the position of the titrated OA because the metal in the OA may cause image artifacts during MRI.

The analysis of the anterior displacement of the condyle used the method advocated by Guimarães.³⁴ This method divides the TMJ into vertical compartments (Figure 2). The Frankfurt hori-

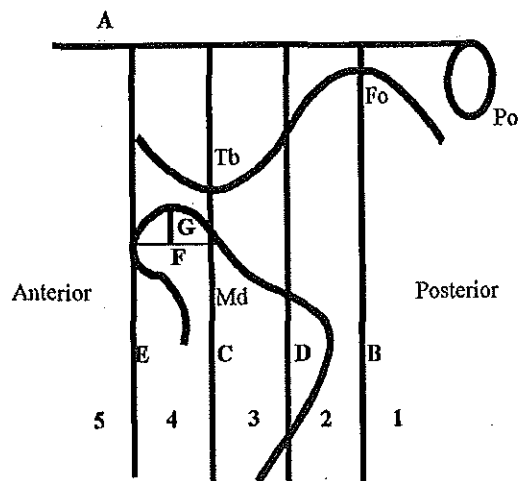


Figure 2—The quantification of mandibular condyle position. Md=mandible; Po=porion; Fo=fossa; Tb=tubercle; A=Frankfurt Horizontal Plane (FH); B=line to FH through the highest point of the fossa; C=line to FH through the center of the eminence; D=line to FH equidistant between B and C; E=line to FH forward of C, the same size as the CD distance; F=line parallel to FH through the maximum AP distance of condyle head; G=line to FH drawn from midpoint of the F line. Compartments are numbered 1 to 5 from posterior to anterior.

zontal plane (A) is drawn and then a line perpendicular to the Frankfurt horizontal plane (B), crossing the highest point of the mandibular fossa, and another line that is also perpendicular to this plane, crossing the articular tubercle vertex (C) are constructed. A third line is drawn in the middle, parallel and equidistant to the two previous lines (D). Following this, one parallel and equidistant line is drawn in the anterior direction (E). Each compartment is assigned a number. The median region of the

condyle is determined by the greatest width of the condyle, on a line parallel to the Frankfurt horizontal plane (F). The reference line (G) perpendicular to the Frankfurt horizontal plane is drawn to determine the compartment where the condyle is located and is identified at the middle of line F.

Sequential Sleep Study Protocol

After clinical evaluation, all patients underwent baseline polysomnography and MRI. The subjects were then instructed to wear the OA every day during the entire night. Once the patients were accustomed to wearing the appliance, a second sleep study evaluated the 60% forward mandibular position of the mandible. If the symptoms and sleep study did not show an important decrease in OSA signs, the dentist advanced the appliance in increments of 0.5 mm per week. Once the bed partner reported a cessation of snoring, a third polysomnogram was undertaken. In the event that the sleep study results were not acceptable, further advancements were performed, and a fourth sleep study was obtained. For each patient a titrated position of the OA was achieved, and the OA was fixed in this position and a follow-up MRI was obtained.

Statistical Analysis

A paired t-test was applied to baseline and posttitration polysomnography results as the variables had a normal distribution according to the Kolmogorov-Smirnov test. To compare the AHI with the amount of mandibular advancement, a linear regression was used. Because of the small number of data, when a linear regression was fitted, we excluded the outlier point, not all of the results from that patient. The results from the MRI assessments were descriptive only.

Table 1—Anthropometric variables and sleep characteristics before and after insertion of the Klearway™ titratable oral appliance.

Patient	Age (years)	BMI (kg/m ²)		AHI (/h TST)		AI (/h TST)	
		Before	After	Before	After	Before	After
1	52	28.7	29.3	13.4	5.9	10.7	4.6
2	48	29.4	29.1	6.7	0.8	1.3	0.0
3	43	27.7	28.4	13.5	4.0	1.2	0.6
4	37	26.3	26.3	23.7	9.8	10.7	6.1
5	48	26.5	28.4	9.7	10.9	8.2	5.5
6	52	25.6	26.2	12.2	6.0	8.0	5.2
Mean	46.67	27.37	27.95	13.20	5.64*	6.68	3.31*
SD	5.79	1.49	1.36	5.76	3.72	3.99	2.66
Min. Sa.O₂ (%)		Stage 2 sleep (%)		Stage 3 and 4 sleep (%)		REM sleep (%)	
Before	After	Before	After	Before	After	Before	After
76.0	87.0	45.6	46.7	32.9	38.2	18.0	13.0
89.4	91.0	60.1	50.9	21.7	41.5	11.2	5.0
75.0	90.0	58.4	57.1	6.2	12.6	18.8	13.9
80.0	76.0	42.6	35.3	31.5	70.8	10.2	19.1
74.0	75.0	68.9	62.1	5.1	32.6	5.9	1.7
78.0	81.0	51.2	51.9	12.2	27.8	21.0	17.1
78.73	83.33	54.47	50.67	18.27	37.25*	14.2	11.6
5.16	6.39	9.86	9.23	12.30	19.30	5.93	6.86

*p<0.05

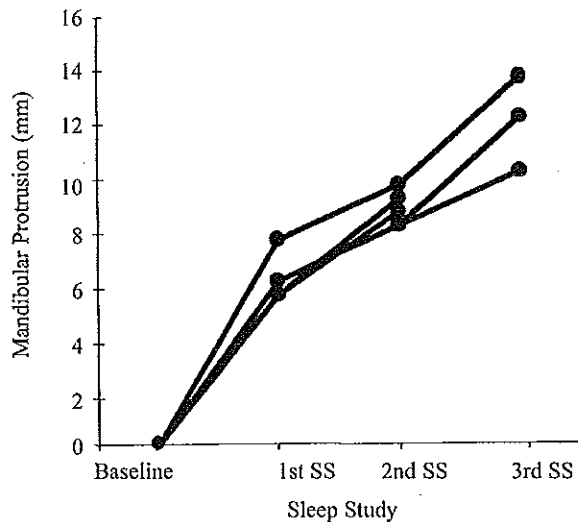


Figure 3—The amount of mandibular protrusion over sequential sleep-study nights. SS= sleep study for five.

Table 2—AHI in different mandibular protrusion positions

Patient	Baseline	POSITION		
		60%	60% + 2.4 mm	60% + 5.3 mm
1	13.4	9.6	9.3	5.9
2	13.5	9.0	8.3	4.0
3	9.7	15.3	9.2	10.9
4	6.7	4.9	0.8	
5	23.7	49.1	9.8	
6	12.2	8.9	6.0	

60%; 60% of maximum protrusion. Unit: millimeter.

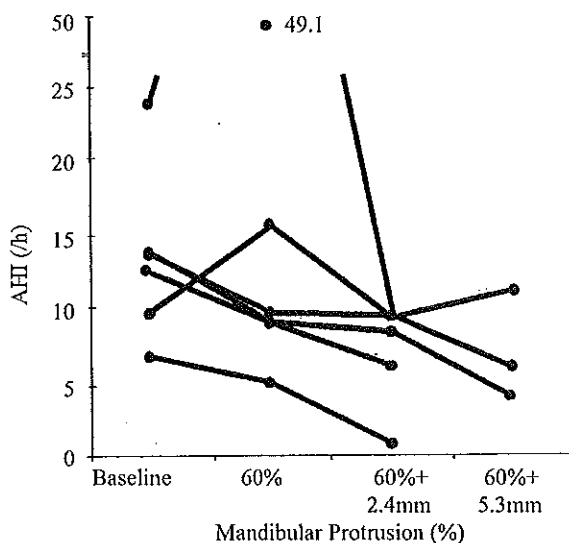


Figure 4—Dose-dependent changes of AHI in response to titration of the mandibular position. 60%= 60% of maximum mandibular protrusion.

RESULTS

Patient characteristics at the time of the study are outlined in Table 1. One of the seven patients (baseline AHI 16/h; minimum SaO₂ 81%) experienced articular pain in the right side of the TMJ region; small adjustments were made in the OA, yet the pain persisted and, for this reason, the patient was advised to discontinue the use of the OA and was excluded from the sequential sleep study protocol. These symptoms appeared after 40 days of OA use with the appliance in the initial position of 60% of maximum mandibular protrusion. The spontaneous pain persisted for 4 weeks, increased during mandibular movements and resolved after 4 weeks of not wearing the OA.

Six patients had a reduction in the mean AHI from 13.2 ± 5.76 to 5.64 ± 3.72 ($p < 0.05$). The apnea index (AI) had a mean reduction from 6.68 ± 3.99 to 3.31 ± 2.66 ($p < 0.05$); in addition there was a significant increase in the percentage of slow wave sleep ($p < 0.05$). In five patients, a reduction of AHI below 10 was seen, associated with a reduction of 50% of the baseline AHI (Table 1).

Progressive mandibular advancements were performed during the titration period, based on the clinical and polysomnographic criteria (Figure 3). The mean amount of mandibular protrusion during titration was 6.2 mm at the first sleep study, 8.6 mm at the second, and 11.7 mm (3 patients only) at the third sleep study. After the final titration period, the average mandibular protrusion was 10.3 ± 1.6 mm, as shown in Figure 3.

The average evaluation period for the six patients from baseline to final polysomnography was 9.09 ± 3.71 months. Although we could not identify the reason, one patient showed an increase in AHI only at 60% of mandibular advancement. Four patients showed a decrease of AHI with increased mandibular advancement. Three patients had a total of four sleep studies, including baseline, whereas the rest of the patients had three. The relationship between amount of protrusion and AHI is presented in Table 2 and Figure 4. The amount of mandibular protrusion in this study may be identified as one factor that decreased the AHI ($r = -0.516$ and $p = 0.02$) (Figure 5).

The evaluation period from the initial MRI to the titrated appliance position lasted from eight to nineteen months with a mean value of 11.52 ± 5.28 months. All of the patients had symmetrical chewing musculature with preserved morphology and signal intensity both before and after treatment. The mandibular fossa and articular eminence also revealed preserved outlines, morphology and signal intensity (Table 3).

Four patients had a normal positioning of the articular disc, one patient had an anterior displacement with reduction, and two patients had anterior displacement without reduction. No changes were seen in the articular disc position when comparing the pre- and post-treatment images. Four patients showed cortical bone structures and resonance signals of the condyle within normal standards, both before and after treatment. One patient initially had a discrete reduction of the upper cortical area in the left condyle, while in the second examination this same patient showed a similar alteration but on the right condyle. In the other two patients, osteophytes were seen in both joints; that is, irregularities in the condyle without changes after the placement of the appliance.

In order to better understand the nature of this problem, MRI of the TMJ were undertaken after symptoms disappeared, with and without the appliance prototype in position. Table 3 summa-

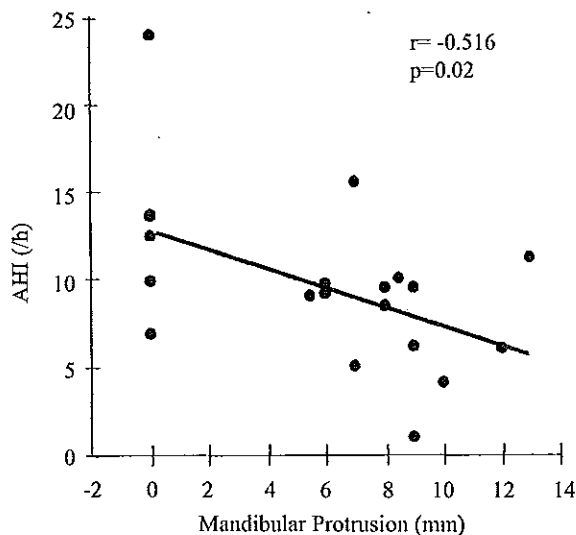


Figure 5—Linear regression of AHI and the amount of mandibular advancement. Note that an extraordinary AHI number (49.1) in Figure 4 was excluded.

rizes the anterior-posterior displacement of the 14 joints of the seven evaluated patients. In 13 joints, the anterior displacement of the condyle was always less or equal to that with the appliance in place when compared to maximum opening. On the right side of patient #7, who was instructed to discontinue OA use due to articular pain on the right side, the condyle reached a more anterior compartment while wearing the OA, when compared to maximum mouth opening.

DISCUSSION

The results of this study confirm that the OA used is an effective treatment for OSA, reducing apneas and hypopneas. Based on the current study, effect of the OA on the AHI is related to the amount of mandibular protrusion. In addition, the appliance did not cause any significant change in the morphology of the TMJ over the time period of the study, and the anterior displacement of the condyle with the appliance in place appeared to be within the physiologic limits of the TMJ except in one patient. Thus, the titratable OA reproduced a therapeutic position where the AHI is effectively reduced and the condyle is in an acceptable location.

There is a known relationship between an increase in BMI and increasing severity of OSA.³⁵ As well, OAs have a better response when used for mild to moderate¹ sleep apnea patients who have a lower BMI.³⁶ However, in our study we observed one patient with an increased BMI and, paradoxically, an improvement of OSA. The only patient who had no AHI improvement gained six kilos during treatment, but showed a decreased AI and the bed partner reported a cessation of snoring. One patient initially became worse with the use of the OA, and only with further advancement did his AHI improve to 9.8. Some patients whose OSA initially became worse with OA therapy may need greater advancement of the mandible.

Similar to nCPAP, where nasal pressure is titrated for each patient to reduce the AHI, the concept of titration is important with respect to the amount of protrusion in OA therapy. Raphaelson and coinvestigators²⁷ progressively advanced the mandible of six patients and showed a relationship between mandibular advancement and AHI; however, the study was done during a full-night polysomnography in which patients got up to change their mandibular position. In the present study, the mandibular advancements were performed over nine months so that the TMJ had enough time to become accustomed to more advanced positions; in addition, a full-night study was done for each position to avoid the problem of a questionable split-night

Table 3—MRI anatomic parameters observed before and after treatment with the Klearway™ appliance and a comparison of the translation of the condyle by compartment.

Patient	Parameter	Muscles, fossa and eminence		Condyle		Disc position		Condyle Translation	
		Before	After	Before	After	Before	After	MO	OA
1	L	n	n	tsi	n	n	n	5	2
	R	n	n	n	tsi	n	n	5	2
2	L	n	n	n	n	n	n	5	3
	R	n	n	n	n	n	n	5	4
3	L	n	n	n	n	n	n	5	3
	R	n	n	n	n	n	n	5	3
4	L	n	n	op	op	AWoR	AWoR	2	2
	R	n	n	op	op	AWoR	AWoR	2	2
5	L	n	n	n	n	n	n	6	3
	R	n	n	n	n	n	n	5	4
6	L	n	n	n	n	AWR	AWR	3	2
	R	n	n	n	n	AWR	AWR	3	2
7	L	n	n	op	op	AWoR	AWoR	3	3
	R	n	n	op	op	AWoR	AWoR	2	3

L= left joint; R= right joint; n= within the limits of normality; op= osteophyte; tsi= tiny surface irregularity; AWR= anterior disc displacement with reduction; AWoR= anterior disc displacement without reduction; MO= maximal opening; OA= oral appliance.

study. Evaluating sleep apnea patients with three OAs with 2, 4, and 6 mm of mandibular advancement, Kato and coinvestigators⁹ assessed home overnight oximetry for each of the three mandibular positions. They found that for each 2 mm of mandibular advancement, the oxygen desaturation index improved by 20% and demonstrated the dose-dependent effect of mandibular advancement on blood oxygen levels. Choi and co-investigators³⁷ evaluated the airway resistance among OSA patients in the normal jaw position, 1/3 forward, 2/3 forward, and maximum (3/3) mandibular protrusion and observed that the resistance quantitatively decreased relative to the degree of protrusion. Morphologically, Tsuki and coworkers³ analyzed ten nonapneic adults with supine lateral cephalograms in four mandibular positions (as used by Choi et al.³⁷ above) and demonstrated, with the same OA used in our study, that the anteroposterior width of the velopharynx increases after two-thirds of maximum protrusion. We speculated the reduction of the AHI being significantly dependent on the amount of mandibular protrusion would be supported by those reports.

Interestingly, in three patients, the resolution of symptoms did not show an adequate reduction of the AHI, therefore, further advancement was done and a fourth sleep study was completed. These findings suggest that the OA titration should be controlled with polysomnography or some other objective measurement, such as home oximetry, which is currently used as a screening and follow-up assessment for better OA treatment success.

The literature contained several articles about the side effects of OAs on the TMJ, but to our knowledge, this is the first report to examine the TMJ with MRI. When we analyzed the morphology and signal intensity of the TMJ with MRI (Table 1), the appliance did not produce any observable remodeling of the TMJ during the study period. In one study, remodeling of the articular tuberosity and the condyle was found in young adults up to 19 years of age after 12 weeks of orthodontic treatment and continued until the end of treatment at 8.5 months.^{38,39} Our study was performed on subjects over the age of 25 years and remodeling features were not seen in any of the cases after 11.5 months. This suggests that the appliance does not significantly alter the TMJ, but long-term studies with a greater sample size are still required to determine whether there is a remodeling of the TMJ or neighboring structures after two or more years. Bondenmark⁴⁰ and Bondenmark & Lindman⁴¹ observed 32 patients after two years of continuous OA use. Minor occlusal changes were seen with lateral head radiographs; the authors hypothesized a TMJ remodeling, although the imaging method used is not as specific as MRI is for TMJ evaluation.

With respect to the MRI results, it was observed that the only patient who presented with pain while using the OA had an anterior displacement of the condyle superior to the displacement seen with maximum opening. This patient had an overbite of 9 mm and, therefore, a greater degree of mouth opening was required to insert and seat the appliance. It seems obvious that patients who did not develop pain had condyles within the physiological limits of TMJ movements. If the translation of the condyle surpasses the physiologic limits, it may result in articular pain possibly due to the distention of the posterior attachment of the articular disc or the TMJ articular capsule. But there may be other factors, since many patients with deep overbites are able to use OAs. The use of MRI for the assessment of condyle displacement with an appliance prototype may be an ideal method

of evaluating whether the use of OAs is compatible with the articular dynamics of patients.

There are some limitations to this study. The titration period of the OA of approximately five months is longer than that required for nCPAP, but once patients tolerate the OA, the compliance is better than with nCPAP.¹⁰ We recognize that the small sample size is another limitation of this study. However, due to polysomnography expenses and lack of patient compliance for many repeat sleep studies, we completed the analysis of only seven patients. Therefore, further studies will be necessary to confirm the polysomnographic and MRI results and subsequent conclusions cited in this study. Nevertheless this is the first study to document the results of sequential sleep studies in different mandibular positions as well as MRI evaluations of the joint in patients who use OA.

In conclusion, sequential polysomnographic studies facilitate OA titration. Improvements in the AHI are dependent on the amount of mandibular advancement. MRI is an important method of evaluating the TMJ in patients undergoing OA treatment, not only to determine the long-term side effects, but also to evaluate the articular dynamics. In spite of the small sample size and short observation period, OAs in the titrated position appear to be innocuous to the TMJ in OSA patients.

ACKNOWLEDGEMENTS

The authors wish to thank Dr. Antonio S. Guimarães for the critical review of the TMJ data, Dr. Benjamin Wolf Handfas for the MRI tutorial, and Dr. Ana M. Tamelini for her MRI analysis. We are grateful for the statistical analysis provided by Ms. Mary Wong. We would also like to thank Mrs. Ingrid Ellis for her editorial assistance in the final preparation of the manuscript. This study was supported by Associação Fundo de Incentivo à Psicofarmacologia, São Paulo, Brazil. The Klearway™ appliance was invented by one of the authors (AAL), and international patents have been obtained by The University of British Columbia. Specific licensees are assigned the rights to manufacture and distribute the appliance worldwide.

REFERENCES

1. Lowe AA, Sjöholm TT, Ryan CF, Fleetham JA, Ferguson KA, Remmers JE. Treatment, airway and compliance effects of a titratable oral appliance. *Sleep* 2000;23(4):S172-S178.
2. Cohen R. Obstructive sleep apnea: oral appliance therapy and severity of condition. *Oral Surg Oral Med Oral Pathol* 1998;85(4):388-392.
3. Tsuki S, Hiyama S, Ono T, Imamura N, Ishiwata Y, Kuroda T, Lowe AA. Effects of a titratable oral appliance on supine airway size. *Sleep* 2001;24(5):554-560.
4. Ryan CF, Love LL, Peat D, Fleetham JA, Lowe AA. Mandibular advancement oral appliance therapy for obstructive sleep apnoea: effect on awake caliber of the velopharynx. *Thorax* 1999;54:972-977.
5. Lowe AA. Can we predict the success of dental appliance therapy for the treatment of obstructive sleep apnea based on anatomic considerations? *Sleep* 1993;16:S93-S95.
6. Gao XM, Zeng XL, Fu MK, Huang XZ. Magnetic resonance imaging of the upper airway in obstructive sleep apnea before and after oral appliance therapy. *Chin J Dent Res* 1999;2(2):27-35.
7. Schmidt-Nowara W. Recent developments in oral appliance therapy of sleep disordered breathing. *Sleep Breath* 1999;3:103-106.
8. Tsuki S, Ono T, Kuroda T. Mandibular advancement modulates respiratory-related genioglossus electromyographic activity. *Sleep and Breathing* 2000;4(2):53-57.

9. Kato J, Isono S, Tanaka A, et al. Dose-dependent effects of mandibular advancement on pharyngeal mechanics and nocturnal oxygenation in patients with sleep-disordered breathing. *Chest* 2000;117:1065-1072.
10. Ferguson KA, Love LL, Ryan CF. Effect of mandibular and tongue protrusion on upper airway size during wakefulness. *Am J Respir Crit Care Med* 1997;155:1748-1754.
11. Clark GT, Sohn JW, Hong CN. Treating obstructive sleep apnea and snoring: assessment of an anterior mandibular positioning device. *JADA* 2000;131:765-771.
12. Pantin CC, Hillman DR, Tennant M. Dental side effects of an oral device to treat snoring and obstructive sleep apnea. *Sleep* 1999;22(2):237-240.
13. Tegelberg A, Wilhelmsson BO, Walker-Engström ML, Ringkvist M, Andersson L, Krekmanov L, Ringkvist I. Effects and adverse events of a dental appliance for treatment of obstructive sleep apnea. *Swed Dent J* 1999; 23: 117-126.
14. Bonham PE, Currier FC, Orr WC, Othman J, Nanda RS. The effect of a modified functional appliance on obstructive sleep apnea. *Am J Orthod Dentofacial Orthop* 1988;94(5):384-392.
15. Ichioka M, Tojo N, Yoshizawa M, Chida M, Miyazato I, Taniai S, Marumo F, Nakagawa K, Hasegawa M. A dental device for treatment of obstructive sleep apnea: a preliminary study. *Otolaryngol Head Neck Surg* 1991;104(4):555-558.
16. Nakazawa Y, Sakamoto T, Yasutake R, Yamaga K, Kotorii T, Miyahara Y, Ariyoshi Y, Kaneyama T. Treatment of sleep apnea with prosthetic mandibular advancement (PMA). *Sleep* 1992;15(6):499-504.
17. Eveloff SE, Rodsenberg CL, Carlisle CC, Millman RP. Efficacy of a Herbst mandibular advancement device in obstructive sleep apnea. *Am J Respir Crit Care Med* 1994;149:905-909.
18. O'Sullivan RA, Hillman DR, Mateljan R, Paantín C, Finucane KE. Mandibular advancement splint: an appliance to treat snoring and obstructive sleep apnea. *Am J Respir Crit Care Med* 1995;151:194-198.
19. Ferguson KA, Ono T, Lowe AA, Kennan SP, Fleetham JA. A randomized crossover study of an oral appliance vs nasal-continuous positive airway pressure in the treatment of mild-moderate obstructive sleep apnea. *Chest* 1996;109(5):1269-1275.
20. Ferguson KA, Ono T, Lowe AA, Al-Majed S, Love LL, Fleetham JA. A short term controlled trial of an adjustable oral appliance for the treatment of mild to moderate obstructive sleep apnoea. *Thorax* 1997;52:362-368.
21. Menn SJ, Loube DI, Morgan TD, Mitler MM, Berger JS, Erman MK. A mandibular repositioning device: role in the treatment of obstructive sleep apnea. *Sleep* 1996;19(10):794-800.
22. Pancer J, Al-Faifi S, Al-Faifi M, Hoffstein V. Evaluation of variable mandibular advancement appliance for treatment of snoring and sleep apnea. *Chest* 1999;116(6):1511-1518.
23. Schmidt-Nowara W, Meade TE, Hays MB. Treatment of snoring and sleep apnea with a dental orthosis. *Chest* 1991;99:1378-1385.
24. Clark GT, Arand D, Chung E, Tong D. Effect of anterior mandibular positioning on obstructive sleep apnea. *Am Rev Respir Dis* 1993;147:624-629.
25. Clark GT, Blumenfeld I, Yoffe N, Peled E, Lavie P. A crossover study comparing the efficacy of continuous positive airway pressure with anterior mandibular positioning devices on patients with obstructive sleep apnea. *Chest* 1996;109(6):1477-1483.
26. Bernhold M, Bondenmark L. A magnetic appliance for treatment of snoring patients with and without obstructive sleep apnea. *Am J Orthod Dentofacial Orthop* 1998;113(2):144-154.
27. Raphaelson MA, Alpher EJ, Bakker KW, Perlstrom JR. Oral appliance therapy for obstructive sleep apnea syndrome: progressive mandibular advancement during polysomnography. *J Craniomand Pract* 1998;16(1):44-50.
28. Rechtschaffen A, Kales A. A manual of standardized terminology, techniques and scoring system for sleep stages of human subjects. Los Angeles: UCLA Brain Information Service, 1977.
29. American Academy of Sleep Medicine Task Force Report. Sleep related breathing disorders in adults: recommendations for syndrome definitions and measurement techniques in clinical research. *Sleep* 1999;22:667-689.
30. Lowe AA. Oral appliances for sleep breathing disorders. In Kryger MH, Roth T, Dement WC eds. [Principles and practice of sleep medicine], 3rd edition, Philadelphia, WB Saunders, 2000;929-939.
31. American Sleep Disorders Association Standards of Practice Committee. Practice parameters for the treatment of snoring and obstructive sleep apnea with oral appliances. *Sleep* 1995;18(6):511-513.
32. George PT. A new instrument for functional appliance bite registration. *J Clin Orthod* 1992;26(11):721-723.
33. Katzberg RW. Temporomandibular joint imaging. *Radiology* 1989;170(2):297-307.
34. Guimarães AS. Temporomandibular joint: analysis pseudodynamic magnetic resonance imaging [dissertation]. São Paulo (SP): Universidade Federal de São Paulo; 1998.
35. Young T, Palta M, Dempsey J, Skatrud J, Weber S, Badr S. The occurrence of sleep-disordered breathing among middle age adults. *N Engl J Med* 1993;328:1230-1235.
36. Liu Y, Lowe AA, Fleetham JA, Park YC. Cephalometric and physiologic predictors of the efficacy of an adjustable oral appliance for treating obstructive sleep apnea. *Am J Orthod Dentofacial Orthop* 2001;120(6):639-647.
37. Choi JK, Goldman M, Koyal S, Clark G. Effect of jaw and head position on airway resistance in obstructive sleep apnea. *Sleep and Breathing* 2000;4(4):163-168.
38. Ruf S, Pancherz H. Long-term TMJ effects of Herbst treatment: a clinical and MRI study. *Am J Orthod Dentofacial Orthop* 1998;114(5):475-483.
39. Ruf S, Pancherz H. Temporomandibular joint remodeling in adolescents and young adults during Herbst treatment: a prospective longitudinal magnetic resonance imaging and cephalometric radiographic investigation. *Am J Orthod Dentofacial Orthop* 1999;115(6):607-618.
40. Bondenmark L. Does 2 years' nocturnal treatment with mandibular advancement splint in adult patients with snoring and OSA cause a change in the posture of the mandible? *Am J Orthod Dentofacial Orthop* 1999;116(6):621-628.
41. Bondenmark L, Lindman R. Craniomandibular status and function in patients with habitual snoring and obstructive sleep apnoea after nocturnal treatment with a mandibular advancement splint: a 2-year follow-up. *Eur J Orthod* 2000;22:53-60.